

The Gut-Brain-Axis: A Positive Relationship between Gut Microbial Dysbiosis and Glioblastoma Brain Tumour

**Diagnosis**

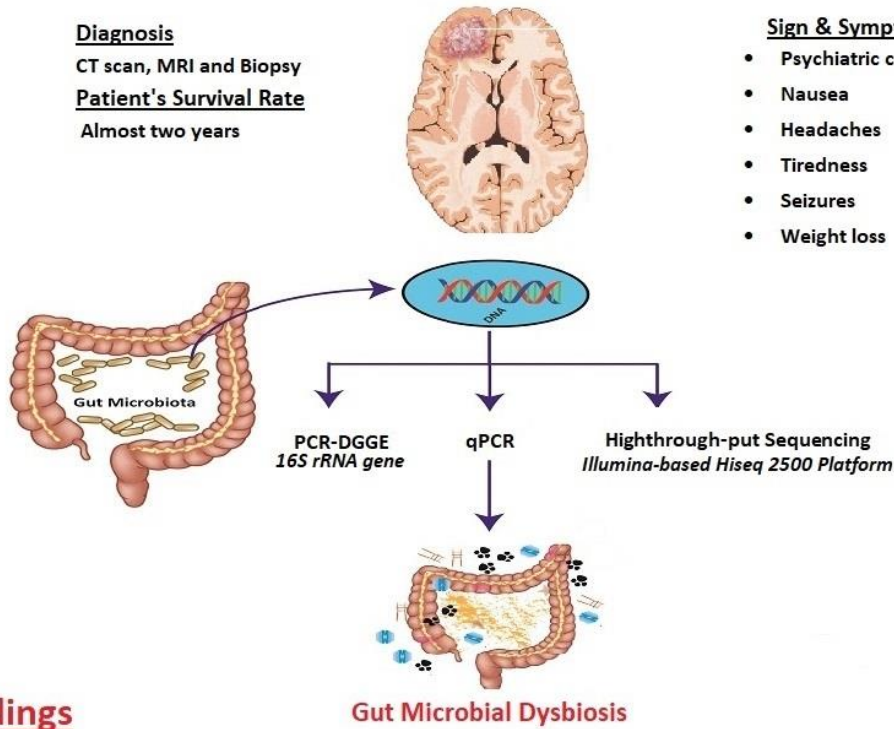
CT scan, MRI and Biopsy

**Patient's Survival Rate**

Almost two years

**Sign & Symptoms**

- Psychiatric conditions
- Nausea
- Headaches
- Tiredness
- Seizures
- Weight loss



**Findings**

**Phylum** Proteobacteria, Firmicutes

**Family** Bacteroidaceae, Lachnospiraceae, Enterobacteriaceae  
Prevotellaceae, Rikenellaceae, Veillonellaceae

**Genus** Escherichia-Shigella, Bacteroides, Parasutterella, Prevotella 9,  
Ruminococcus 2, Faecalibacterium

**Species** Escherichia coli, Bacteroides\_vulgatus

Author: Hafiz Muhammad Ishaq  
Department of Pathobiology & Biomedical Sciences  
MNS- University of Agriculture Multan, Pakistan